Mesenteric ischemia

Amirhossein Faraji M.D

Associate professor of Gastroenterology and Hepatology

I.U.M.S, Tehran, Iran.



Intestinal ischemia

- Intestinal ischemia, which can affect the small or large intestine, can be caused by any process that reduces intestinal blood flow, such as;
- Arterial occlusion
- Venous occlusion
- Arterial vasospasm



CLASSIFICATION;

- Intestinal ischemia can be classified according to;

- The time course of onset and quality of symptoms (Acute mesenteric ischemia and Chronic mesenteric ischemia).
- The degree to which blood flow is compromised
- The segment of bowel that is affected.

- Ischemia affecting the small intestine is generally referred to as mesenteric ischemia, while ischemia affecting the large intestine is referred to as colonic ischemia.

- Acute mesenteric ischemia refers to the sudden onset of small intestinal hypoperfusion, which can be due to;
- Occlusive or nonocclusive obstruction of the arterial blood supply.
- Obstruction of venous outflow.

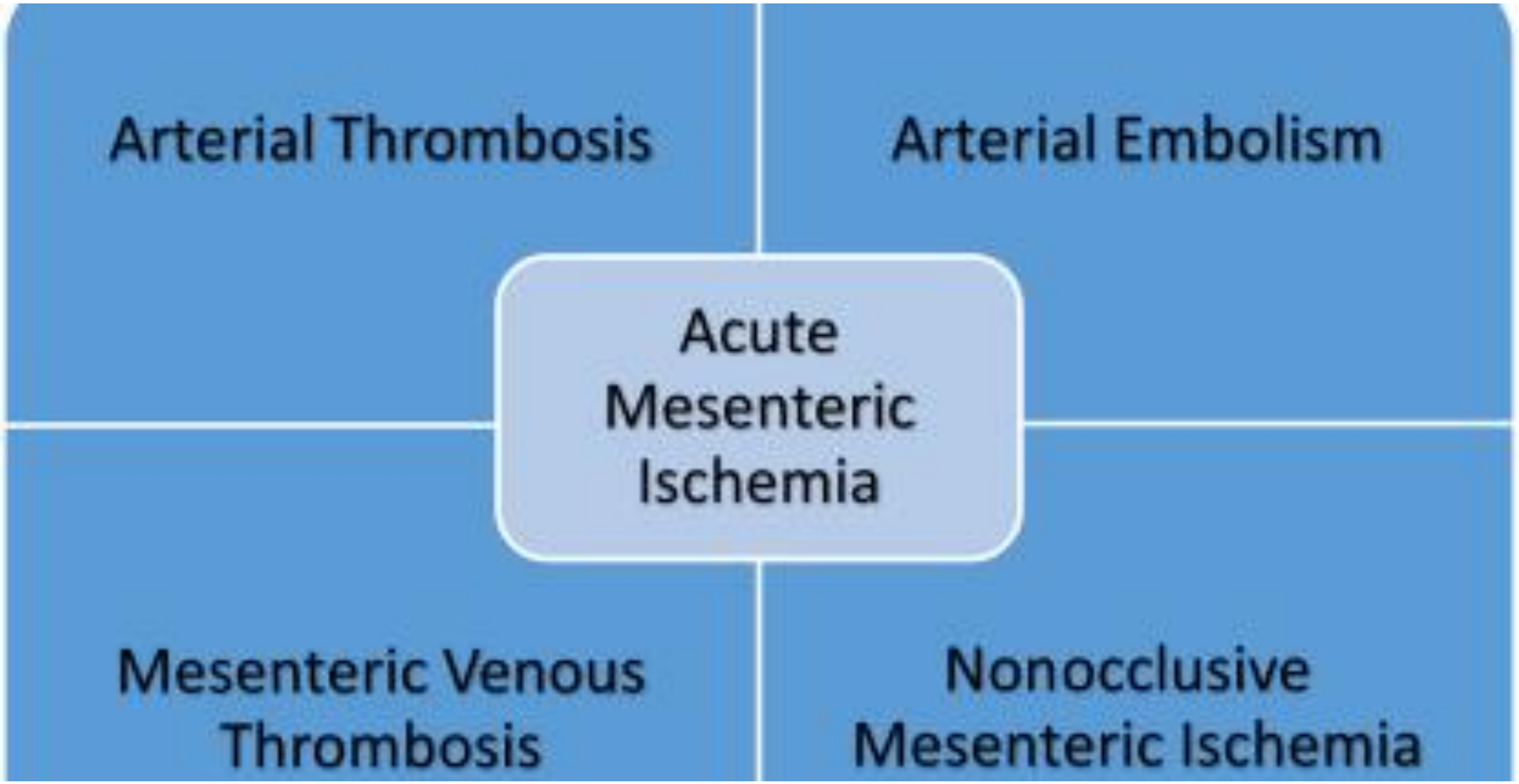
Arterial Thrombosis
Arterial Embolism
Acute Mesenteric Ischemia
Mesenteric Venous Thrombosis
Nonocclusive Mesenteric Ischemia

- Occlusive arterial obstruction is due to an acute embolism or thrombosis and most commonly affects the superior mesenteric artery (SMA).
- Venous thrombosis is due to obstruction of the intestinal outflow tract, including the superior and inferior mesenteric veins and the splenic and portal veins.
- Nonocclusive mesenteric ischemia is a result of a low-flow state and is most commonly due to vasoconstriction from low cardiac output or the use of vasopressors.



- Chronic mesenteric ischemia usually develops in patients with mesenteric atherosclerosis causing episodic intestinal hypoperfusion related to eating.

INTESTINAL VASCULAR ANATOMY

- The arterial supply to the intestines consists primarily of the superior mesenteric artery (SMA) and inferior mesenteric artery (IMA).

- The SMA supplies the entire small intestine except for the proximal duodenum.

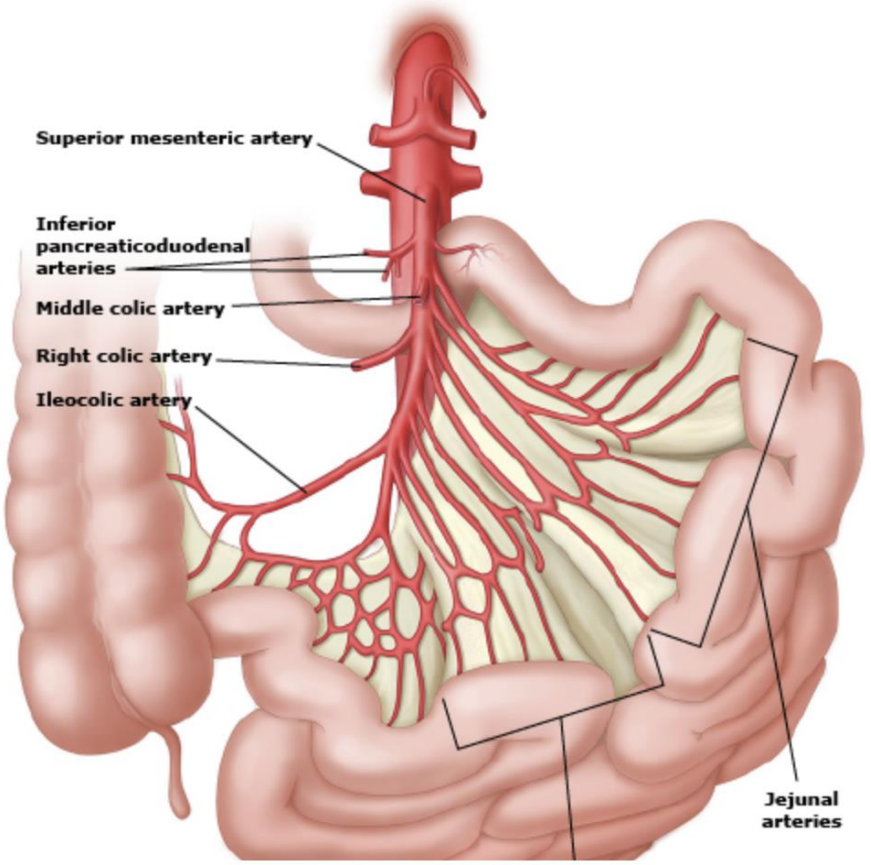

INTESTINAL VASCULAR ANATOMY

- The SMA and IMA both supply the colon.

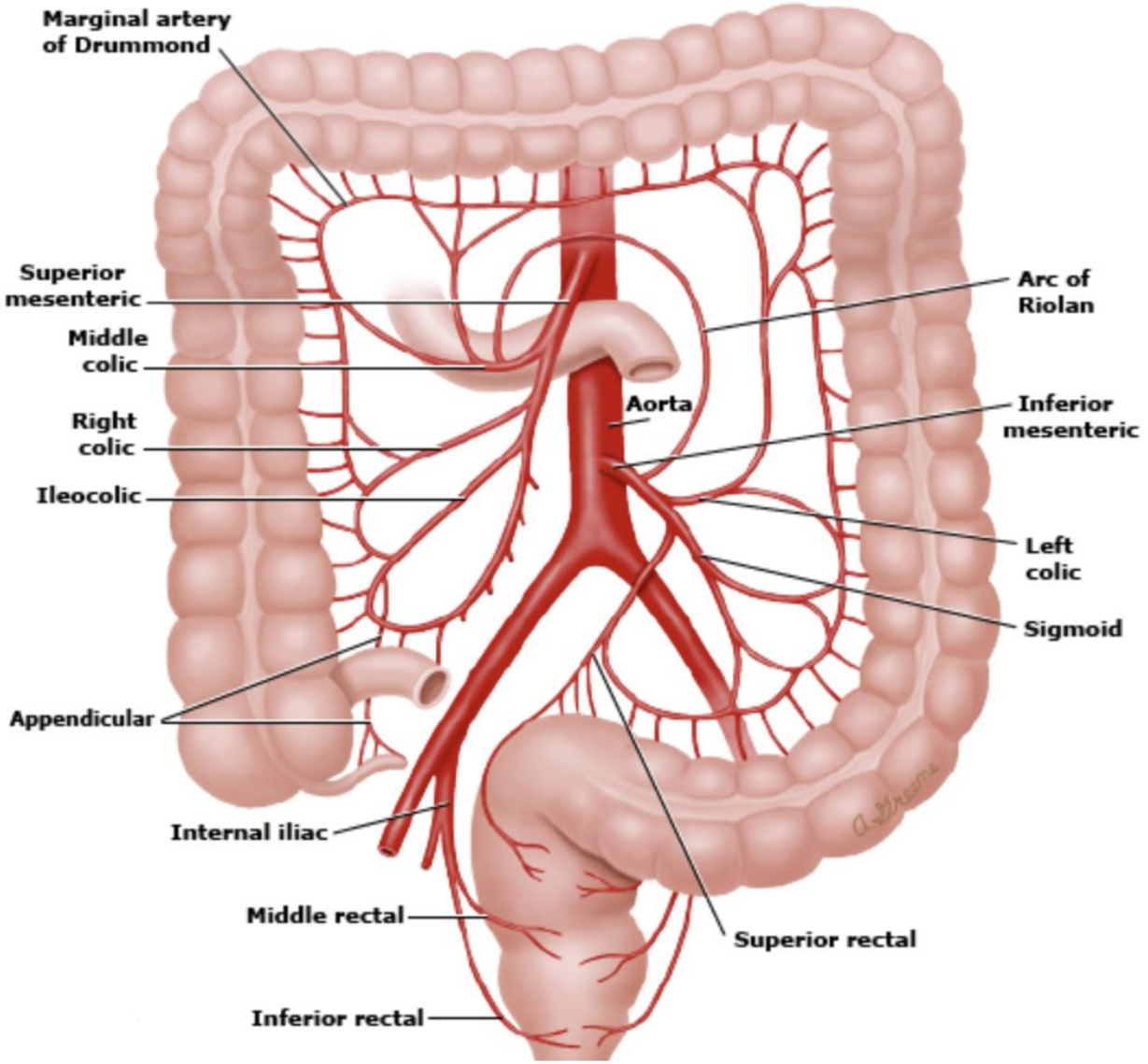

INTESTINAL VASCULAR ANATOMY

The venous drainage parallels the arterial circulation and drains into the portal venous system.

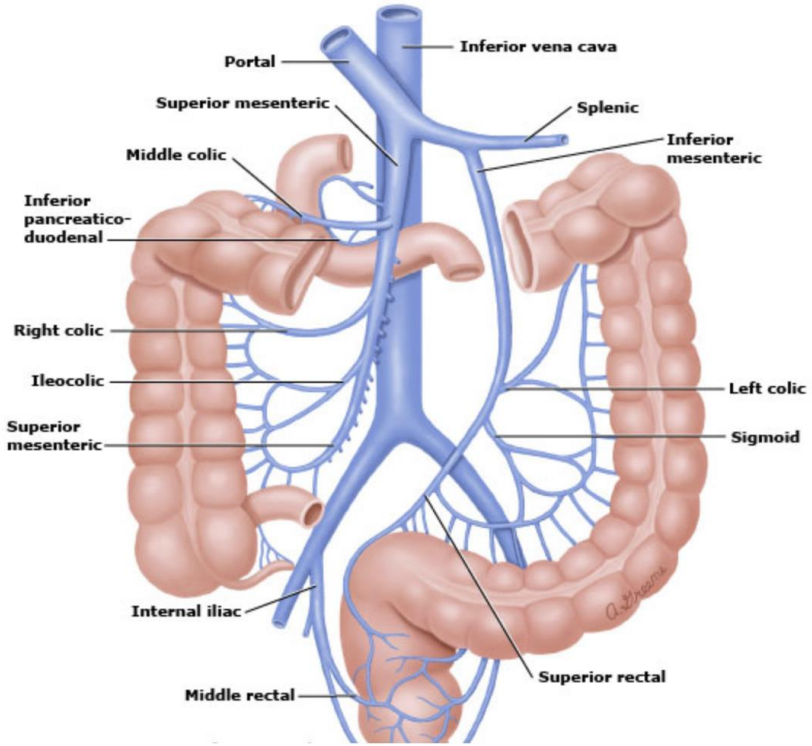

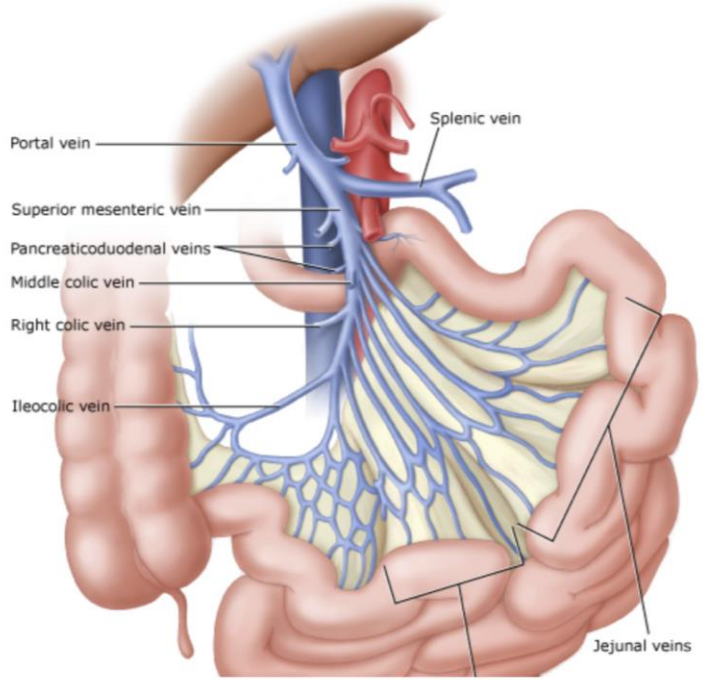



Areas prone to ischemia

- The watershed areas between the major vessels that supply the colon are at risk for ischemia.
- Narrow terminal branches of the SMA supply the splenic flexure (Griffiths' point).
- Narrow terminal branches of the IMA supply the rectosigmoid junction (Sudeck's point).

Normal physiology

The splanchnic circulation receives between 10 to 35 percent of cardiac output, depending upon whether it is in the fed or fasted state.

Although the capillary density within the intestinal vasculature is high compared with other vascular beds, intestinal oxygen extraction is relatively low, thereby permitting sufficient oxygen to be delivered to the liver via the portal vein.

As a result, intestinal blood flow must be reduced by at least 50 percent from the normal fasting level before oxygen delivery to the intestine becomes compromised.

- However, intestinal injury is caused both by tissue hypoxia and reperfusion.
- Reperfusion injury occurs following restoration of blood flow after a period of ischemia.

- It is a complex response characterized by release of free oxygen radicals, toxic byproducts of ischemic injury, and neutrophil activation, which can lead to multisystem organ failure.

Etiologies of ischemia

- Mesenteric arterial embolism (50 percent)
- Mesenteric arterial thrombosis (15 to 25 percent)
- Mesenteric venous thrombosis (5 percent)
- Nonocclusive mesenteric ischemia due to intestinal hypoperfusion (20 to 30 percent).

EPIDEMIOLOGY AND RISK FACTORS

- Acute insufficiency of mesenteric arterial blood flow accounts for 60 to 70 percent of cases of mesenteric ischemia.
- The remainder is related to chronic mesenteric and colonic ischemia.
- The incidence of acute mesenteric ischemia appears to be rising, which may be due, in part, to an increased awareness among clinicians and an aging population with severe cardiovascular and/or systemic disease.
- Another contributing factor may be due to the prolonged survival of critically ill patients.
- In younger patients without cardiovascular disease, mesenteric venous thrombosis is the major cause of acute ischemia of the small bowel.

Table 1 Risk factors for specific types of AMI

From: Acute mesenteric ischemia: updated guidelines of the World Society of Emergency Surgery

	Pathogenesis of AMI			
	Acute mesenteric arterial embolism	**Acute mesenteric arterial thrombosis**	**NOMI**	**Mesenteric venous thrombosis**
Risk factors	Atrial fibrillation recent MI cardiac thrombi Mitral valve disease Left ventricular aneurysm Endocarditis Previous embolic disease	Diffuse atherosclerotic disease Postprandial pain Weight loss	Cardiac failure Low flow states Multiorgan dysfunction Vasopressors Abdominal compartment syndrome	Portal hypertension history of VTE Oral Contraceptives Estrogen use Thrombophilia Pancreatitis
Clinical onset	Sudden strong abdominal pain, vomiting	Progressive or sudden abdominal pain, vomiting, diarrhea and/or melena	Progressive pain, mild	Nonspecific GI symptoms, abdominal distension, worsening of general condition
Vascular involvement	Main artery or branches of SMA	Celiac trunk, SMA, IMA origins	Superior mesenteric vein, progression to portal vein	Stenosis of SMA

AMI Acute mesenteric ischemia; *NOMI* Non-occlusive mesenteric ischemia; *MI* Myocardial infarction; *SMA* Superior mesenteric artery; *IMA* Inferior mesenteric artery; *GI* Gastrointestinal; and *VTE* Venous thromboembolism

CLINICAL FEATURES

- **Abdominal pain** — Abdominal pain is the most common presenting symptom in patients with intestinal ischemia.

- The classic clinical description for acute intestinal ischemia is "abdominal pain out of proportion to the physical examination."
- The onset and severity of pain depends upon the duration of occlusion and the effectiveness of the collateral circulation.

Several features of the pain and its presentation may provide clues to the etiology of the ischemia and help distinguish small intestinal from colonic ischemia.

Acute mesenteric Ischemia (small intestine)	Acute Ischemic Colitis (watershed areas of colon most commonly affected, splenic flexure and rectosigmoid junction)
Patient very ill, age varies, RF include A.fib, infective endocarditis, aortic/ventricular aneurysm, PAD	90 % patients >60 years
Pain out of proportion to exam, tenderness not prominent early	Prominent abdominal tenderness, pain not as prominent
BRBPR uncommon until late	BRBPR common in <24 hours
CTA or angiography to make diagnosis	Colonoscopy to make diagnosis
Etiologies: acute embolic occlusion, most commonly SMA, thrombosis (atherosclerosis)	Etiologies: Non-occlusive colonic ischemia (95 %), embolic/thrombotic arterial occlusion, mesenteric vein thrombosis
Treatment: Anticoagulation, broad spectrum antibiotics, PPI, oxygen, surgical embolectomy aorto-mesenteric bypass, vasodilators	Treatment: supportive care, antibiotics, NOT routinely anticoagulated, ex lap if severe

Mesentric ischemia

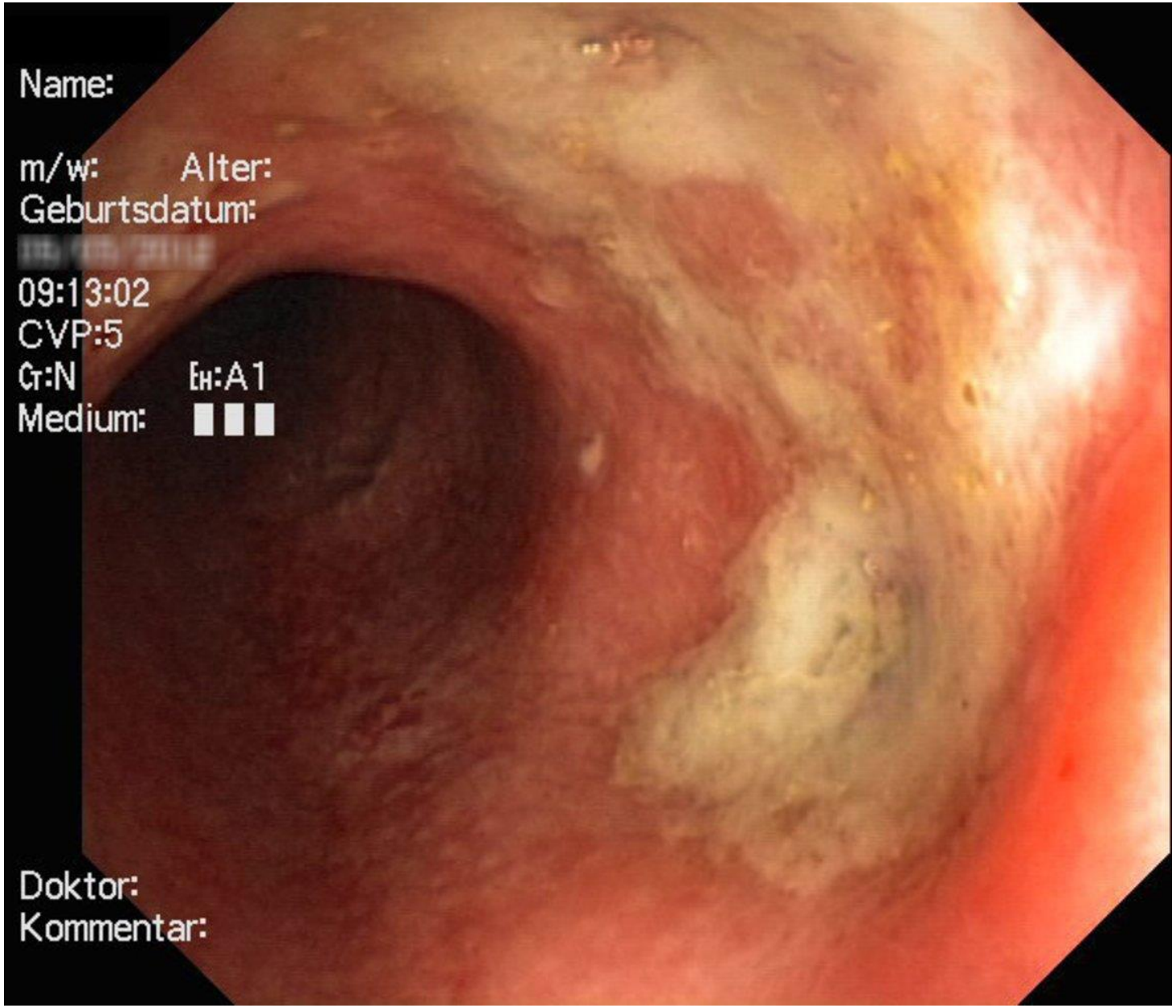

Ischemic Colitis

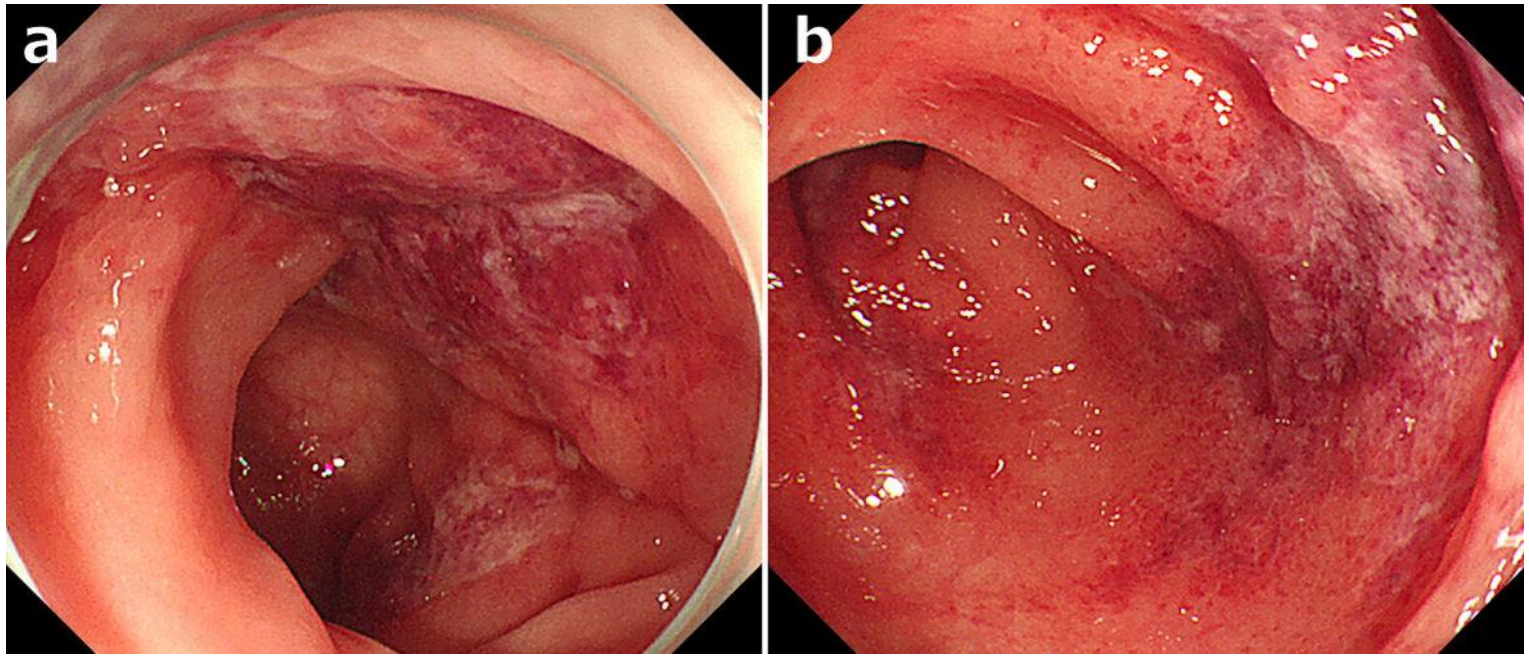

Pain associated with arterial embolism to the proximal superior mesenteric artery is typically sudden, severe, periumbilical, and often accompanied by nausea and vomiting.

Patients with mesenteric venous thrombosis are more likely to present with a more insidious onset of abdominal pain that can wax and wane for a period of time before a diagnosis is established.

Chronic mesenteric ischemia

- Presents as intestinal Angina
- Abdominal pain soon after eating, lasting 1-2 hours
- Patient develops “food fear” and “small meal syndrome”
- Associated weight loss
- Often concomitant atherosclerotic disease elsewhere
- Diabetes and Hypertension often coexist and predispose

Physical examination

The abdominal examination may be normal initially or show only mild abdominal distension with no signs of peritoneal inflammation, such as rebound tenderness and guarding.

Occult blood may be present in the stool.

However, as bowel ischemia progresses and transmural bowel infarction develops, the abdomen becomes grossly distended, bowel sounds become absent, and peritoneal signs develop.

A feculent odor to the breath may also be appreciated.

Signs consistent with dehydration and shock indicate a deteriorating clinical course.

Laboratory studies

- Laboratory studies are nonspecific;
- Normal laboratory values do not exclude acute mesenteric ischemia and do not justify delaying urgent radiologic evaluation when clinical suspicion for acute mesenteric ischemia exists.
- Findings may include;
- Marked leukocytosis with a predominance of immature white blood cells.
- An elevated hematocrit consistent with hemoconcentration.
- Metabolic acidosis; A useful clinical guideline is that any patient with acute abdominal pain and metabolic acidosis has intestinal ischemia until proven otherwise.



A systematic review reported a pooled sensitivity for l-lactate for acute mesenteric ischemia of 86 percent (95% CI 73 to 94 percent) and a pooled specificity of 44 percent (95% CI 32 to 55 percent).

Elevated serum amylase levels have been observed in approximately one-half of patients with intestinal ischemia.

Normal D-dimer levels may help to exclude acute intestinal ischemia, but elevated levels are less useful for making a diagnosis.

Plain radiographs

- Plain abdominal radiography is relatively nonspecific and may be completely normal in more than 25 percent of patients.
- Findings suggestive of mesenteric ischemia include;
- The presence of an ileus with distended loops of bowel
- Bowel wall thickening (particularly prominent in acute mesenteric venous thrombosis).
- Pneumatosis intestinalis may be observed in patients with advanced ischemia.
- Obvious findings, such as free intraperitoneal air, indicate the need for immediate abdominal exploration.



- A plain radiograph of the abdomen demonstrates distended featureless loops of small bowel with wall thickening (arrow) and separation of the bowel loops. These findings are consistent with hemorrhage into the bowel wall secondary to ischemia.

- Panel A is a magnified image of a single fold in the colon demonstrating air within the wall of the colon, which appears as a thin linear lucency on this plain film (arrow). Panel B is a plain film from a 68-year-old male with ischemic bowel, demonstrating numerous linear collections of air within the bowel wall.

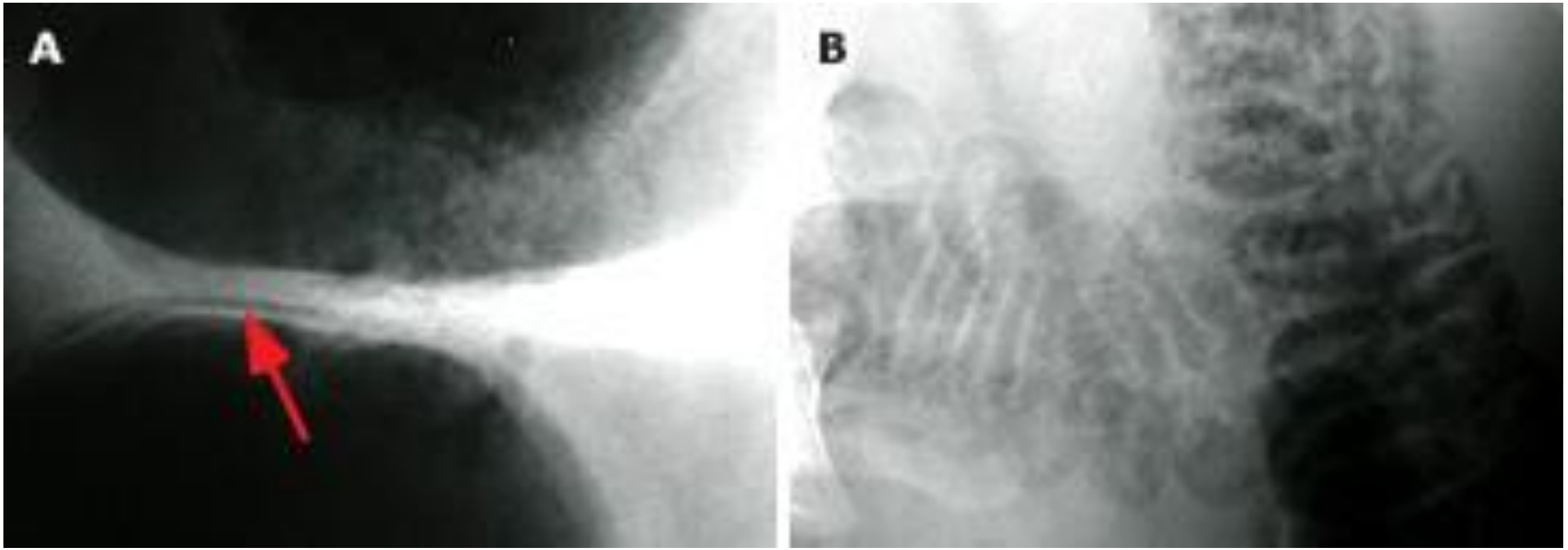

DIAGNOSIS

- Rapid diagnosis is essential among patients with clinical features and risk factors suggestive of intestinal ischemia to reduce the potential for intestinal infarction, although these are generally nonspecific

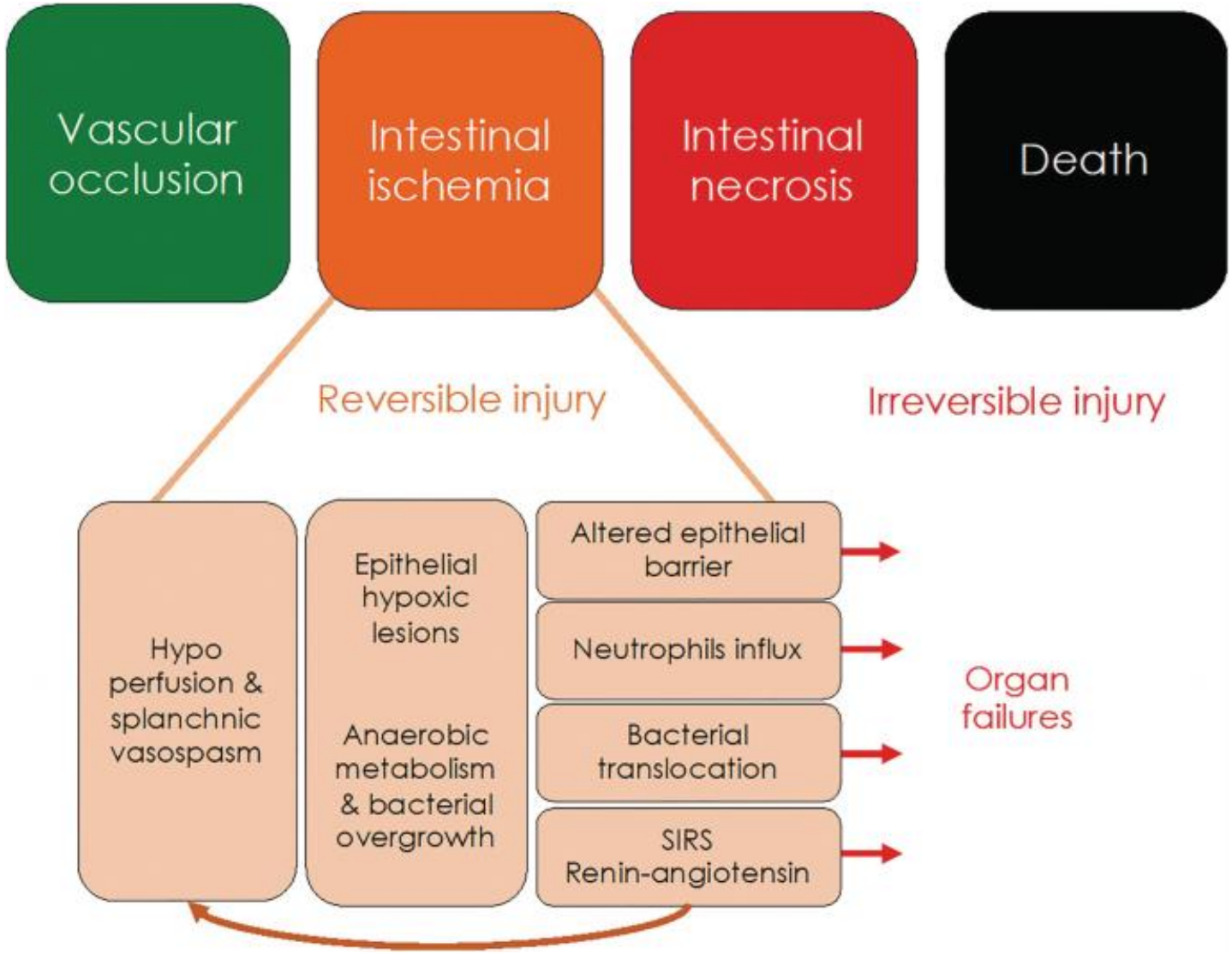

Intestinal ischemia should be considered a potential diagnosis in any critically ill patient who is deteriorating without adequate explanation.

For patients who present with peritonitis or obvious bowel perforation, the diagnosis will necessarily be made in the operating room.

For those without indications for immediate abdominal exploration, a definitive diagnosis requires advanced abdominal imaging. We recommend computed tomographic (CT) angiography as the initial test for most patients with clinical features consistent with intestinal ischemia.

Although duplex ultrasound can identify arterial stenosis or occlusion of the celiac or superior mesenteric arteries, the test is often technically limited by the presence of air-filled loops of distended bowel. In addition, the sensitivity of duplex is limited for detecting more distal emboli or in the assessment of nonocclusive mesenteric ischemia.

Colonoscopy or sigmoidoscopy is often required to establish or confirm the diagnosis of ischemic colitis.

In cases of vasculitis, which typically affects the small- and medium-diameter arteries, stenoses and/or microaneurysms may be detected on arteriography typically without evidence of obstruction of the main mesenteric arteries.

Advanced abdominal imaging

Abdominal CT is commonly used to screen hemodynamically stable patients with acute abdominal pain.

For patients in whom the index of suspicion for intestinal ischemia is high, multidetector CT angiography and magnetic resonance (MR) angiography have improved the ability to diagnose acute mesenteric ischemia.

The CT scan should be performed **without** oral contrast, which can **obscure** the mesenteric vessels, obscure bowel wall enhancement, and can lead to a **delay** of the diagnosis.

The origins of the celiac axis and superior mesenteric artery should also be evaluated for the presence of calcification that indicates an underlying atherosclerotic process as a possible etiology for mesenteric ischemia.

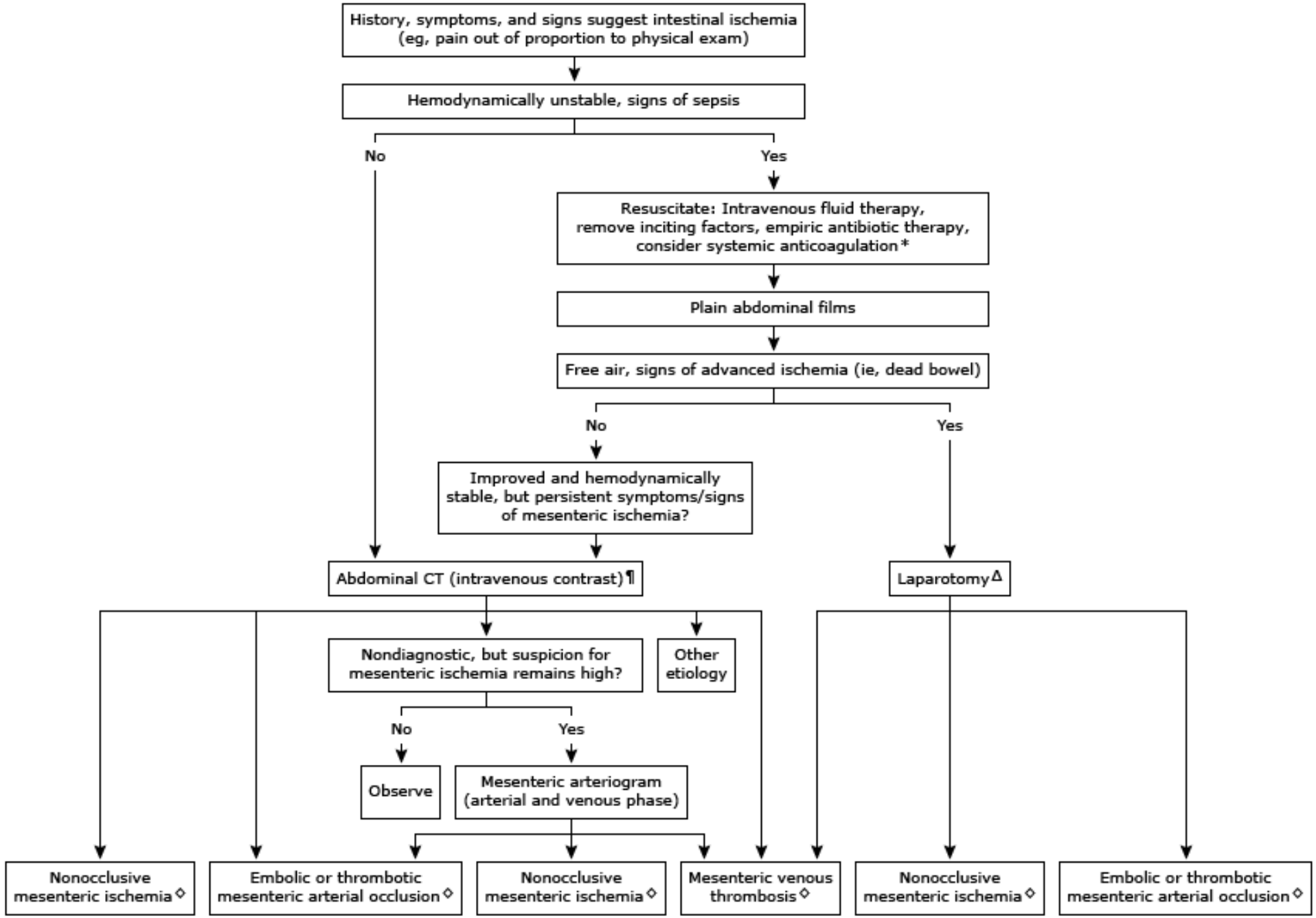
History, symptoms, and signs suggest intestinal ischemia (eg, pain out of proportion to physical exam)
Hemodynamically unstable, signs of sepsis
No
Yes
Resuscitate: Intravenous fluid therapy, remove inciting factors, empiric antibiotic therapy, consider systemic anticoagulation*
Plain abdominal films
Free air, signs of advanced ischemia (ie, dead bowel)
No
Yes
Improved and hemodynamically stable, but persistent symptoms/signs of mesenteric ischemia?
Abdominal CT (intravenous contrast)¶
Laparotomy Δ
Nondiagnostic, but suspicion for mesenteric ischemia remains high?
Other etiology
No
Yes
Observe
Mesenteric arteriogram (arterial and venous phase)
Nonocclusive mesenteric ischemia ◇
Embolic or thrombotic mesenteric arterial occlusion ◇
Nonocclusive mesenteric ischemia ◇
Mesenteric venous thrombosis ◇
Nonocclusive mesenteric ischemia ◇
Embolic or thrombotic mesenteric arterial occlusion ◇

- CT is preferred over MR because of its lower costs, speed, and wide availability.
- However, MR angiography may be more sensitive for the diagnosis of mesenteric venous thrombosis and may be necessary for those with an allergy to iodinated contrast.

CT scan demonstrate findings consistent with acute ischemia;

- Focal or segmental bowel wall thickening.
- Intestinal pneumatosis with portal vein gas
- Bowel dilation
- Mesenteric stranding
- Portomesenteric thrombosis
- Solid organ infarction
- Ruling out other causes of acute abdominal pain.

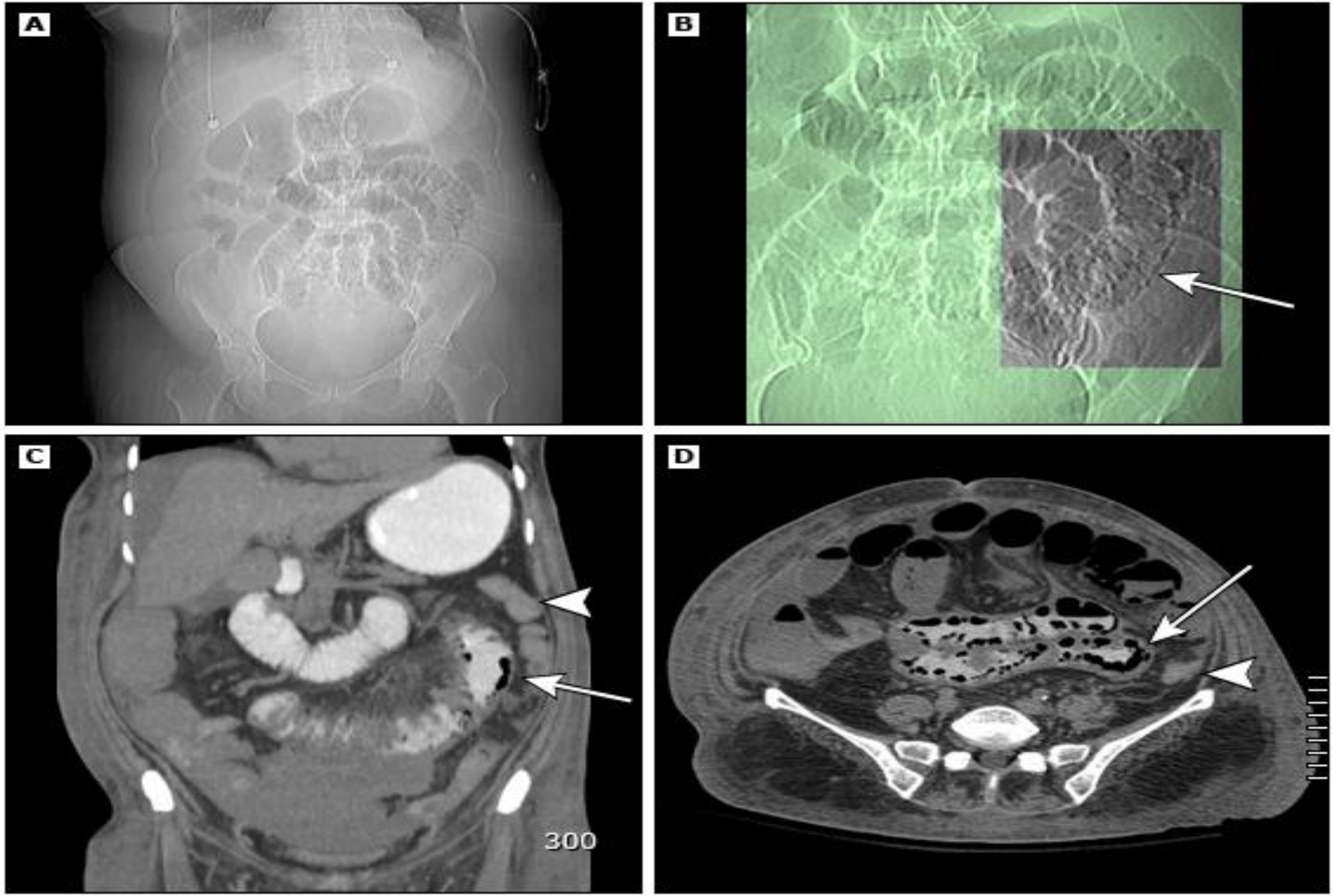
A
B
C
D
300

INITIAL MANAGEMENT

- Gastrointestinal decompression
- Fluid resuscitation
- Hemodynamic monitoring and support
- Correction of electrolyte abnormalities
- Pain control
- Anticoagulation
- Broad-spectrum antibiotics

ABDOMINAL EXPLORATION

- Surgery should not be delayed in patients suspected of having intestinal infarction or perforation based upon clinical, radiographic, or laboratory parameters, regardless of etiology.

TREATMENT OF SPECIFIC ETIOLOGIES

Mesenteric arterial occlusion

The traditional treatment of acute mesenteric arterial embolism is early surgical laparotomy with embolectomy, which may be the preferred treatment for patients with a solitary, proximal superior mesenteric embolus, since it provides rapid treatment and allows direct inspection of the bowel.

An alternative but less established approach for acute embolus, particularly in those with severe comorbidities, is local infusion of a thrombolytic agent; however, this option is reserved for patients with a shorter duration of symptoms and without signs of peritonitis.

For mesenteric arterial thrombosis, choices include surgical revascularization, or thrombolysis with endovascular angioplasty and stenting.

The choice depends on the time course, severity of ischemia, and medical comorbidities of the patient.

- Mesenteric venous thrombosis
- Anticoagulation may be all that is needed in the treatment of patients with mesenteric venous thrombosis.

- Nonocclusive mesenteric ischemia
- The treatment of nonocclusive mesenteric ischemia focuses on removing inciting factors (vasoconstrictive medications), treating underlying causes (heart failure, sepsis), hemodynamic support and monitoring, and intra-arterial infusion of vasodilators, if necessary.

OUTCOMES

The outcomes related to the treatment of intestinal ischemia depend upon the mechanism.

Survival of an acute ischemic event is worse for patients with an arterial etiology compared with a venous etiology.

For acute mesenteric ischemia, mortality rates exceed 60 percent.

Patients who survive an acute event are likely to die of complications related to the underlying condition that predisposed them to intestinal ischemia.

Thanks for your attension

